



Fractured Teeth

Traumatic dental fractures may occur under different circumstances. Dogs will commonly fracture their teeth when chewing aggressively on a toy that is too hard, such as bones, antlers or hooves. Some dogs have been known to fracture teeth when chewing or biting on the bars of their kennels. Cats may fracture their teeth during a fight or when struck by a car.




Uncomplicated vs complicated crown fractures

Tip fractures or chip fractures are when only the enamel is damaged and broken away. These are called uncomplicated fractures as they do not involve the deeper structures such as the pulp cavity (where the blood vessel is).

Complicated crown fractures are teeth that have broken deep enough to involve the pulp cavity. These teeth will often bleed when they break and are very painful. Once the pulp cavity is exposed, the tooth is at very high risk of tooth root abscesses occurring and will remain uncomfortable. Dental radiographs (x-rays) and a complete oral exam are done to identify infection.

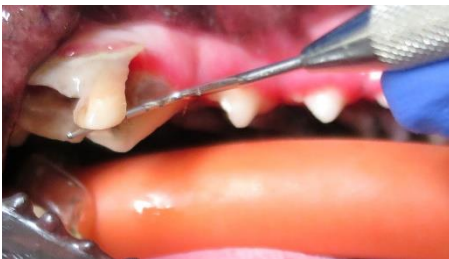A tooth that fractured a long time ago is still uncomfortable. We can see evidence of this being the case when we examine the mouth. They often will avoid chewing on that tooth and will chew on the opposite side of the mouth instead. This results in the affected side having heavy tartar build up from disuse and the unaffected side having less tartar buildup. With time periodontal disease will start to occur with bone loss around the tooth.



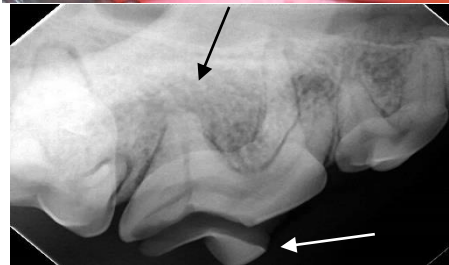Rule of thumb for chew toys

- If something is going to break, it should be the toy, not the tooth!
- Toys should be able to bend slightly and not hurt when bounces off your knee
- If you cannot make a slight indent with your thumb nail, it is too hard

Treatment of fractured teeth



The primary goal for our animal's mouths are to have a pain-free and function bite. It is better to not have the tooth than to have a tooth that is responsible for constant pain and infection. Extraction is recommended for teeth with complicated fractures of infection. Root canals can be performed in recently fractured teeth with referral to a veterinary dental surgeon.



Uncomplicated fractures still require monitoring as with time, they may indeed affect the deeper structures and have associated infections. Uncomplicated fractures can be capped with referral to a veterinary dental surgeon.

Figures: Complicated crown fracture of a carnassial tooth seen with probe lifting the "slab fracture". Note the slab fracture broken away from the tooth on the x-ray (white arrow) and infected root (black arrow).